International Journal of Clinical Medicine Research
2015; 2(2): 4-7
Published online April 20, 2015 (http://www.aascit.org/journal/ijcmr)
ISSN: 2375-3838

Keywords
Persistent Glaucoma,
Pars Plana Vitrectomy (PPV),
Silicone Oil Removal

Received: March 30, 2015
Revised: April 7, 2015
Accepted: April 8, 2015

Persistent Glaucoma After Silicone Oil Removal in Patients Underwent Conventional Pars Plana Vitrectomy: Incidence, Risk Factors and Causes

Ahmad Abd El-Aliem[1], Ahmad Elsayed Hudieb[2]

[1]Ophthalmology, Ain Shames University, Cairo, Egypt
[2]Ophthalmology El Azhar University, Cairo, Egypt

Email address

ahmed.abdelalim540@yahoo.com (A. A. El-Aliem), ahmadhodieb2013@gmail.com (A. E. Hudieb)

Citation

Ahmad Abd El-Aliem, Ahmad Elsayed Hudieb. Persistent Glaucoma After Silicone Oil Removal in Patients Underwent Conventional Pars Plana Vitrectomy: Incidence, Risk Factors and Causes. *International Journal of Clinical Medicine Research.* Vol. 2, No. 2, 2015, pp. 4-7.

Abstract

Purpose: To evaluate the incidence, risk factors and causes of persistent glaucoma after silicone oil removal in patients underwent conventional pars plana vitrectomy (PPV) for complicated Retinal Detachment (R.D). *Materials and Methods:* The study was done in Ain Shames University, Faculty of Medicine, Ophthalmology department in the period between Feb. 2013 and Oct. 2014.It is a prospective study included 80 patients underwent conventional vitrectomy for different vitreoretinal diseases, In all patients silicone oil will be removed after surgery from 3-14(Average 8.5 months) months with follow- up after silicone oil removal from 1-10months (average 5.5months). Persistent IOP rise will be defined by IOP more than 21mmHg which persists after silicone oil removal for 6 weeks Incidence of persistent IOP rise will be estimated, together with risk factor and cause in each case. *Results:* The incidence of glaucoma after silicone oil removal was found to be 42.5% ;46 patients with normal IOP and 34 patients with high IOP and the average IOP in normal patients varying from 9 mmHg to 22 mmHg (average 15.5mmHg) and in glaucomatous patients was 26 mmHg to 50 mmHg (38mmHg). In the glaucomatous patients the risk factors were found to be: Long duration of RD before surgery in 12 patients (15%), Diabetes in 10 patients (12.5%), Long duration of silicone oil(more than 6 months) in 4 patients (5%), Trauma in 2 patients (2.5%), Aphakia in 2 patients (2.5%), Previous glaucoma in2 patients (2.5%), High myopia in1 patient (12.5.%), Multiple surgeries in 1 patient (1.25%).Examination of the anterior chamber angle using gonioscopy revealed narrow angle (grade 2) in 46patient(57.5%) all of them had normal IOP, the other group of high IOP(34 patients) showed very narrow angel (grade 1) in 12 patients (15%), closed angle (grade 0)in 8 patients(10%), Peripheral Anterior Synechial (PAS) in 14 patients (17.5%). *Conclusion:* Persistent glaucoma after silicone oil removal is not uncommon occurrence after silicone oil removal. The underlying mechanism may often be multifactorial in nature. Various risk factors also may be present, and so long follow for these patients is recommended to evaluate the proper treatment.

1. Introduction

Pars plana vitrectomy with Silicone oil tamponed has been used in the treatment of complex retinal detachment for many years [(1)]

Many complications are associated with this procedure such as complicated cataract,

secondaryglaucoma and keratopathy even after successful surgery [2].

The frequency of glaucoma after vitrectomy has been reported between 5.9% and 56 %[3].

Various risk factors have been described for this IOP (Intraocular pressure) rise such as aphakia, steroids use, D.M. and preoperative glaucoma, multiple retinal surgeries [4].

Even more elevated nitric oxide related o the oxidative stress in the anterior chamber with subsequent trabecular injury was reported [5].

The occurrence of this IOP rise may be early postoperative due to pupillaryblock, inflammation, pe-existing glaucoma and /or migration of silicone oil in the anterior chamber[6-10].

And it may be late onset and it may persist after silicone oil removal due to chroic inflammation, infiltration of the trabecular meshwork by silicone bubble or synechial angle closure [11-15].

In addition, scleral buckle can impede outflow from the episcleral veins, thereby contributing to inadequate drainage of aqueous from Schlemm's canal, as well as inadequate venous drainage of the ciliary body, making it edematous and more likely to obstruct the angle and so it if combined with silicone oil injection the incidence of glaucoma may be elevated [16]

2. Materials and Methods

The study was done in Ain Shames University, Faculty of Medicine, Ophthalmology department.

It is a prospective study included 80 patients underwent Conventional PPV for different indications.

The following formula was used for sample calculation $\frac{1.96(P)\times(1-P)}{0.0025}$.

In all patients silicone oil was removed after surgery from 3-14mnths (Average 8.5 months) with follow- up after silicone oil removal from 1-10months (average 5.5months).

Persistent IOP rise will be defined by IOP more than 21mmHg which persists after silicone oil removal for 6 weeks.

Incidence of persistent IOP rise was estimated, together with risk factor and cause in each case.

3. Surgical Procedures

All patients underwent standard three-port PPV and additional procedures as appropriate for the retinal pathology, followed by silicone oil injection1000 in 32 cases and 5000 48 cases.

After appropriate time silicone oil removal was done with a three port technique and after complete removal multiple air fluid exchange was done especially in cases with emulsified silicone oil to be sure of complete removal.

Postoperative treatment with topical I % prednisolone acetate and topical antibiotics for I to 2 weeks.

Exclusion criteria: Cases underwent suturelessvitrectomy, cases combined with scleral buckle.

4. Results

The study included 31 males (38%) and 49 females (62%).

The patients ages ranged from 7 to 70 years (mean ± standard deviation, 47.6 ± 21.3 years). The mean overall follow-up for patients before their having undergone silicone oil removal or glaucoma surgery was 9.6 ± 1.1 months (range, 1 to 10 months).

Regarding the clinical diagnosis: 50 (62.5%) eyes with Proliferative Vitreoretinopathy (PVR), 25 (31.4 %) eyes with advanced proliferative diabetic retinopathy "PDR", 3 (3.75 %) eyes each with severe ocular trauma and 2 patients (2.5) with giant retinal tears .table (1).

The incidence of persistent glaucoma after silicone oil removal was found to be 42.5%;46 patients with normal IOP and 34 patients with high IOP.

The average IOP in normal patients ranged from 8 to 22 mmHg (mean ± standard deviation, 10.7 ± 5.1 mmHg), and in glaucomatous patients ranged from 21.1 to 48.9 mmHg (mean ± standard deviation, 39.7 ± 8.3 mmHg).

In the glaucomatous patients the risk factors were found to be:Long duration of RD before surgery in 12 patients (15%), Diabetes in 10 patients (12.5%), Long duration of silicone oil(more than 6 months) in 4 patients (5%) , Trauma in 2 patients (2.5%), Aphakia in 2 patients (2.5%), Previous glaucoma in2 patients (2.5%), High myopia in1 patient (1.25.%), Multiple surgeries in 1 patient (1.25%), table (2).

Examination of the anterior chamber angle using gonioscopy revealed narrow angle (grade 2) in 46 patient (57.5%) all of them had normal IOP, the other group of high IOP (34 patients) showed very narrow angel (grade 1) in 12 patients (15%), closed angle (grade 0)in 8 patients(10%), Peripheral Anterior Synechial (PAS) in 14 patients (17.5%), table (3).

Table (1). *Clinical classifications of the cases with its number and percentage*

Diagnosis	Number of cases	Percentage
R.D. with Proliferative Vitreoretinopathy	56	62.5%
R.D. with advanced proliferative diabetic retinopathy	25	31.4 %
Severe ocular trauma,	3	3.75%
R.D. with giant retinal tears	2	2.5%

Table (2). *Risk factors of glaucoma, number and percentage.*

Risk factor	Number	Percentage
Long duration of RD before surgery	12	15%
Diabetes	10	12.5%
Long duration of silicone oil	4	5%
Trauma	2	2.5%
Aphakia	2	2.5%
Previous glaucoma	2	2.5%
High myopia	1	1.25%
Multiple surgeries	1	1.25%

Table (3). *Type of the angle, number of cases and percentage.*

Type of angle by gonioscopy	number	percentage
Grade 2	46	57.5%
Grade 1	12	15%
Grade 0	78	10%
PAS	14	17.5%

Figure (1). *Gonioscopic examination shows emulsified oil in the angle*

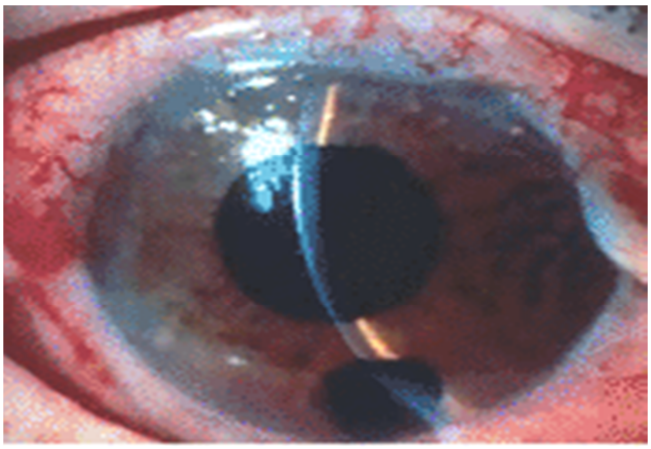

Figure (2). *Aphakic patient with closed angle.*

5. Discussion

Although the anatomical and visual results obtained from intravitreal silicone oil injection used to manage complicated retinal cases can be encouraging, late complications may preclude satisfactory long-term outcomes, although glaucoma is the second most common postoperative adverse occurrence after silicone oil injection (ranging from 15% to 22%), the mechanisms underlying its development remain controversial. [17]

In other studies the frequency of glaucoma after vitrectomy has been reported between 5.9% and 56 %[3], And it may be late onset and it may persist after silicone oil removal due to chronic inflammation, infiltration of the trabecular meshwork by silicone bubble or synechial angle closure [11-15].

In a similar study the incidence of persistent glaucoma after silicone oil removal was 17.6% [18]

In our study the incidence of persistent glaucoma after silicone oil removal was 42.5%.

Our incidence of glaucoma is higher than those previously reported; the reasons for this finding are may be related to some reasons, our patients had a more complex pathology and longer waiting time before surgery, irregular follow up, longer duration of silicone oil tamponade or our definition of glaucoma differing from those in other studies.

In a study similar to ours, they found that approximately 40% of patients who developed glaucoma associated with silicone oil removal had oil in the anterior chamber[19]

In our series, 12% of eyes had silicone oil infiltrating the anterior chamber.

Various risk factors have been described for this IOP rise such as aphakia, steroids use , D.M., preoperative glaucoma and multiple retinal surgeries Even more elevated nitric oxide related to the oxidative stress in the A.C. with subsequent trabecular injury was reported. [4]

In our study; the risk factors were found to be:Long duration of RD before surgery in 12 patients (15%), Diabetes in 10 patients (12.5%), Long duration of silicone oil(more than 6 months) in 4 patients (5%) , Trauma in 2 patients (2.5%), Aphakia in 2 patients (2.5%), Previous glaucoma in2 patients (2.5%), High myopia in1 patient (1.25.%), Multiple surgeries in 1 patient (1.25%).

In a similar study; tauma, aphakia, diabetes mellitus , preoperative glaucoma and silicone oil tamponade more than 12 weeks were found as statistically significant factors , the others factors such as myoia, scleral buckle, emulsified silicone oil, pupilary block and angle synechia were not found as significant factors.[18]

And so our results were similar to that of the other series.

Regarding gonioscopic examination; in our study narrow angle(grade 2) were found in 46 patient(57.5%) all of them had normal IOP, the other group of high IOP(34 patients) showed very narrow angel (grade 1) in 12 patients (15%), closed angle (grade 0)in 8 patients(10%), Peripheral Anterior

Synechial (PAS) in 14 patients (17.5%).

In a study evaluated the effect of vitrectomy with silicone oil tamponade on intraocular pressure and anterior chamber morphology; gonioscopic examination revealed presence of emulsified bubble in the anterior chamber in 22.22% of patients and narrowing of the angle I several patients and adhesion of the angle in 13.33% of patients[20]

And so, the results of both studies emphasis that presence of silicone oil causes significant morphological changes in the anterior chamber angle with subsequent development of glaucoma.

6. Conclusion

In summary, lOP elevation is a common occurrence after silicone oil removal used in the management of complicated retinal cases. The underlying mechanism is often unclear, and may frequently be multifactorial in nature, it also may be early onset (within 1st 6 weeks) or persistent after 6 weeks and so, the patients should be monitored closely for the development of persistent glaucoma especially if they have any risk factors which were listed before.

They may benefit from aggressive medical and or surgical treatment of to avoid additional optic nerve damage.

And so our recommendations are: -

- Do vitrectomy as early as you can because the long waiting period increases the incidence of glaucoma.
- Short duration of silicone oil tamponade (not more than 3 months), we are running a study to demonstrate the effective time for silicone tamponade after which it is useless.
- Trial to avoid silicone oil tamponade as much as we can especially in high risk patients in which long acting gas can be used instead.
- Performing sutureless vitrectomy techniques when available to decrease the conjuctival scarring which will increase the success rate of further glaucoma surgery.

References

[1] Cibis PA, Becker B, Okun E, Canaan S.: The use of liquid silicone in retinal detachment surgery. Arch Ophthalmol 1962;68: 590-9.

[2] Leaver PK, Grey RHB, Garner A.: Silicone oil injection in the treatment of massive preretinal retraction. II. Late complications in 93 eyes. Br. J. Ophthalmol 1979; 63: 361-7.

[3] Gedde SJ. :Management of glaucoma after retinal detachment surgery. Current Opinion in Ophthalmolology. 2002; 13(2): 103-9. Review.

[4] Al-Jazzaf AM, Netland PA, Charles S: Incidence and management ofelevated intraocular pressure after silicone oil injection. J. Glaucoma.2005;14(1):40-6.

[5] Paulo Escariao, Silvio de Bisi, et al: Nitric oxide levels in the anterior chamber of vitrectomized eyes with silicon oil. Revista Brasileira de Oftalmologia.vol.72no.5 Rio de Janeiro Sept./Oct.2013.

[6] Leaver PK, Grey RHB, Garner A :(Silicone oil injection inthe treatment of massive pre retinal traction II. Late complications in 93 eyes. Br. J. Ophthalmol.1979 63:361–367

[7] Federman JL, Schubert HD : Complications associated withThe use of silicone oil in 150 cases after retina-vitreous surgery. Ophthalmology 1988 95:870–876

[8] Zborowski-Gutman L, Triester G, Naveh N, Chen V, Blumenthal M :Acute glaucoma following vitrectomy and silicone oil injection. Br J Ophthalmol1987, 71:903–906

[9] Burk LL, Shields MB, Proia AD et al: Intraocular pressure following in travitreal silicone oil injection. Ophthalmic Surg 1988, 19:565–569

[10] Jonas JB, Knorr HL, Rank RM, Budde W M: Intraocular pressure and silicone oil endotamponade. J Glaucoma, 2001 10:102–108

[11] De Corral LR, Cohen SB, Peyman GA Effect of intravitreal silicone oil on intraocular pressure. Ophthalmic Surg1987, 18:446–449

[12] Ni C, Wang W, Albert DM, SchepensCL :Intravitrealsilicone injection. Histopathologic findings in a human eye after12 years. Arch Ophthalmol1983, 101:1399–1401

[13] Leaver PK, Grey RHB, Garner A : Silicone oil injection inthe treatment of massive pre retinal traction II. Late complications in 93 eyes. Br J Ophthalmol1979, 63:361–367

[14] Henderer JD, Budenz DL, Flynn HW et al : Elevatedintraocular pressure and hypotony following silicone oil retinal tamponade for complex retinal detachment: Incidence and risk factors. Arch Ophthalmol1999, 117:189–195

[15] Budenz DL, Taba KE, Feuer WJ et al :Surgical management of secondary glaucoma after pars plana vitrectomy Graefes Arch Clin Exp Ophthalmol (2009) 247:1585–1593 1591

[16] Ando F :Intraocular hypertension resulting from pupillary block by silicone oil. Am J Ophthalmol1985, 99(1):87-88

[17] Al-Jazzaf AM, Netland PA, Charles S: Incidence and management of elevated intraocular pressure after silicone oil injection. J Glaucoma 2005, 14(1):40-46

[18] R.Zhioua, et al: Chronic Elevated Intraocular Pressure Following Silicone Oil Tamponade for Complex Retinal Detachment Incidence and Risk Factors: European Vitreo Retial Society;2013

[19] Jonas JB, Knorr HL, Rank RM, Budde WM: Intraocular pressure and silicone oil endotamponade. J Glaucoma 2001, 10:102-108.

[20] Popovic et al: The Effect of Vitrectomy with Silicone Oil Tamponade on Intraocular Pressure and Anterior Chamber Morphology , Coll Antropol.25 suppl.(2001)117-125.